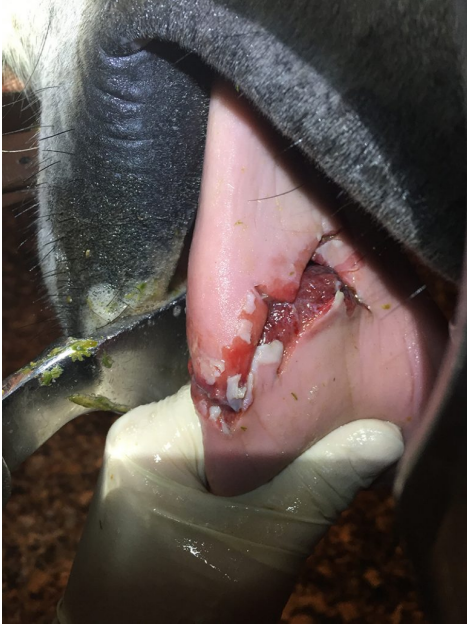

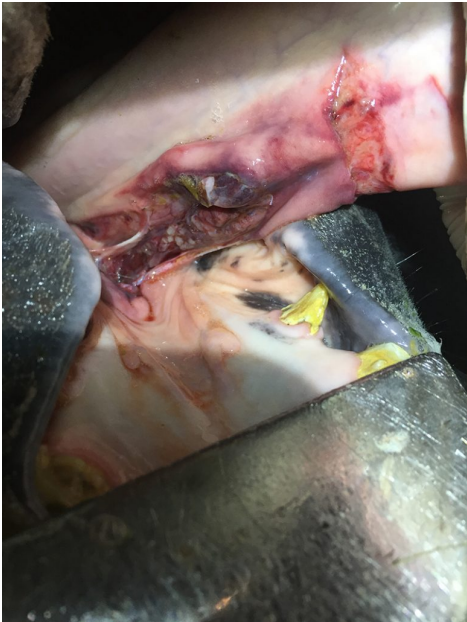
## Lenny's Tongue injury

Back in November, Lenny, a charismatic young dressage horse, was found hyper-salivating, unable to eat or open his mouth and very quiet when his owners did a routine late night check.

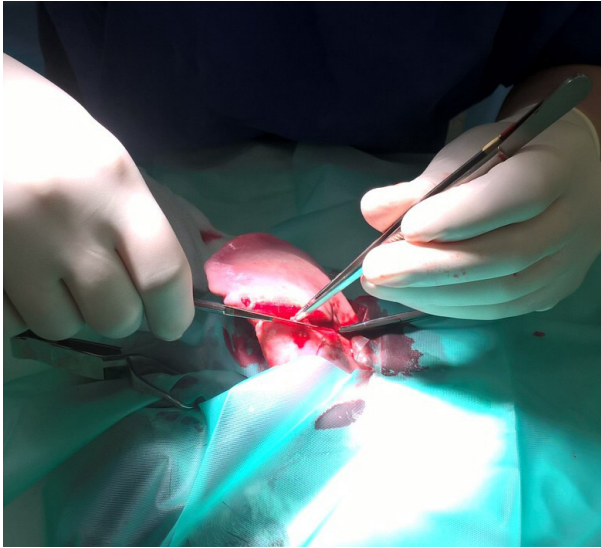
The emergency vet was called and Hattie attended to find a very unusual injury to Lenny's tongue. The tongue had an almost full thickness jagged laceration to the top surface with a complete tear of the frenulum on the underside (the bit that connects the tongue to the floor of the mouth).



Injury on Hattie's arrival

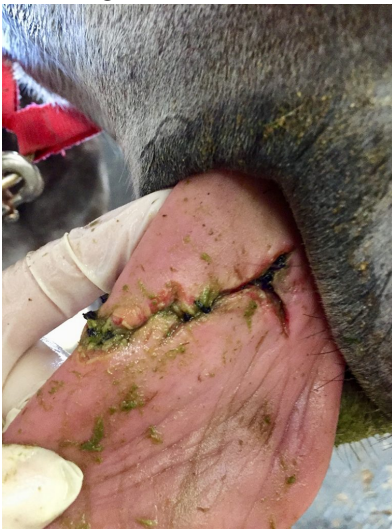

Torn frenulum (underside)



#### During the repair

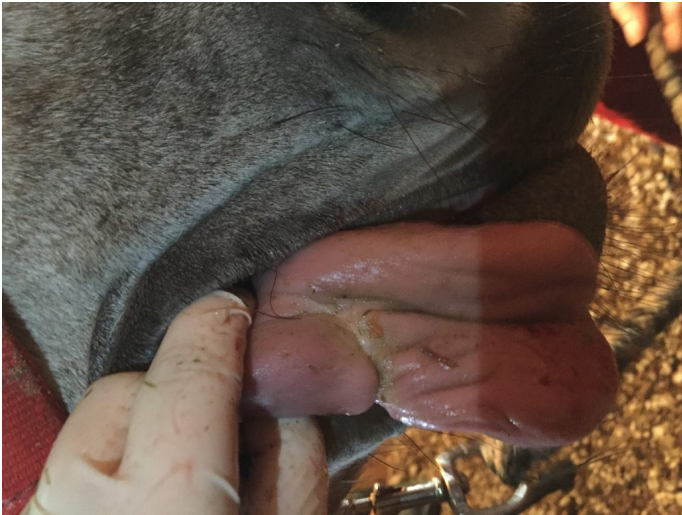Lenny underwent a general anaesthetic first thing in the morning to have the wound cleaned and repaired. Hattie was able to pull the wound together on the surface but left the underside to heal on its own due to the difficulty keeping the stitches in a mobile tongue.



#### 3 days after repair



Lenny recovering



4 weeks after repair

Lenny made an excellent recovery thanks to his very caring owners and is now back in full work with no long term effects from his traumatic autumn evening!



Lenny during dressage