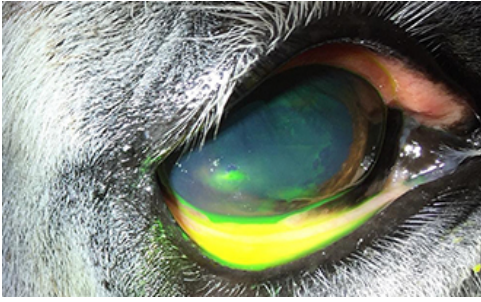
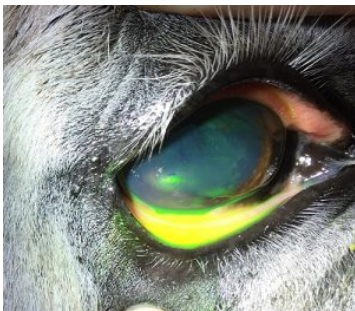
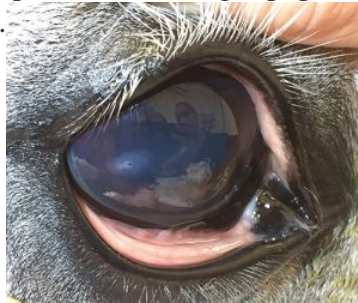
## No EYE in team



Rags' owner had noticed that his right eye looked a little swollen and weepy and over the course of the day it also became cloudy. With concern, his owner called Oakhill Equine Vet, Stuart Davies, to get Rags thoroughly checked. Rags' right eye was partially closed (blepharospasm) and his right pupil was very small - this is a response, by the horse's eye, to discomfort or pain (uveitis).

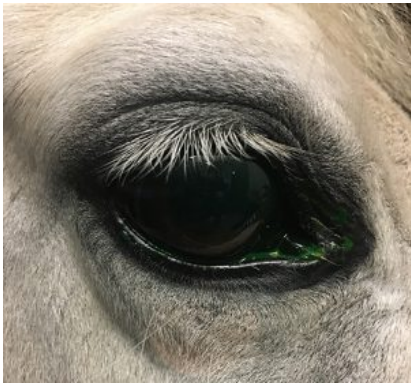
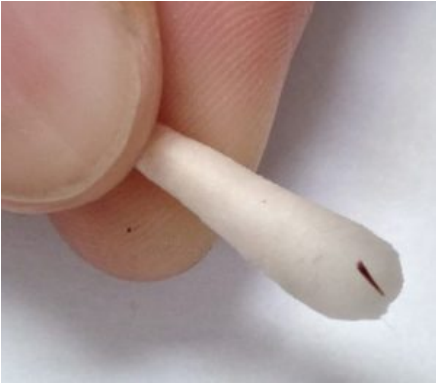
With careful examination using an ophthalmoscope, a very small (only approx 1mm) black object could be seen penetrating the cornea (outer surface of the eye) in the lower left corner of the eye.

Rags was given pain relief, atropine (to dilate the pupil which in itself provides pain relief), then his owner brought him into the Oakhill clinic.

Understandably horses needed to be very cooperative when dealing with their eyes, so Rags was given some sedation and a local anaesthetic block allowing his eye lid to be held open.

Fellow Equine Vet, Jess Wray, then carefully removed the black object that turned out to be a thorn!! Great team work!



Rags was able to continue his pain relief and antibiotic drops at home. A week later you can see his eye is completely back to normal and from now on he will be tuned out with a face mask!

This case demonstrates the importance of careful eye examination. If you notice anything different about your horses eyes, please contact us.