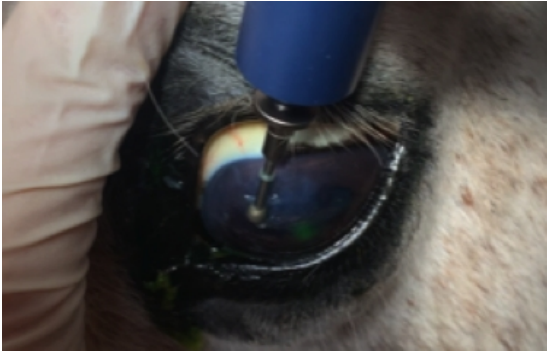
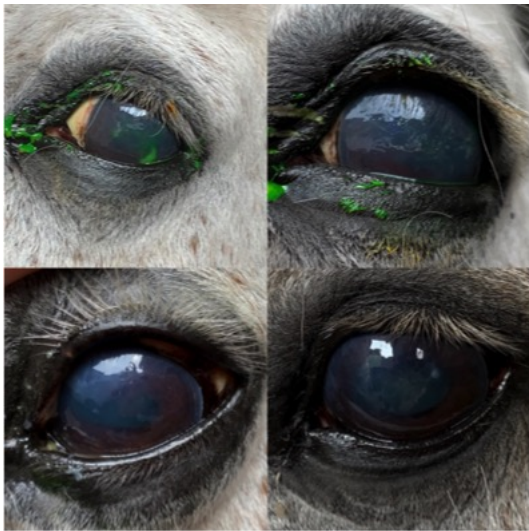

## Stumpy?s corneal ulcers



Stumpy presented to equine vet Jess when his owner noticed a very swollen and closed left eye (blepharospasm) with some discharge (epiphora) after coming in from the field.



On further examination he had damaged the top surface of his eye (cornea) and several areas could be seen after applying some fluorescein dye. This is a very clever dye that will show up as green when it sticks to areas of the cornea that are damaged or ulcerated (see top left image).

Stumpy started different types of eye drops to help promote healing of these lesions and some very strong anti-inflammatories and pain relief to make him feel comfortable and reduce the inflammation in the area. We also decided to put a fly mask on stumpy during turnout to prevent him making it any worse!

However after several weeks Stumpy's corneal ulcers were not healing as quickly as they should and had developed into a chronic condition. New cells in the top layers were not adhering to lower layers and a very irregular surface was developing (see top right image). This required a procedure called corneal debridement with a motorised diamond burr to remove any unhealthy tissue from the corneal surface and speed the healing process.

Video shows Corneal Debridement procedure:

The image on the bottom left shows a much clearer and brighter eye with unhealthy cells removed. The last image shows a completely healed cornea with no ulceration and a shiny smooth regular surface. Result!



**Stumpy and his lovely owner have done so well over the last few months as he hasn't been the easiest to treat with eye drops. We are all so pleased that he is back to normal and enjoying his retirement.**